

## Glenoid Dysplasia: Radiographic, Direct MR Arthrographic and Arthroscopic Appearances

Eoin C. Kavanagh, Adam C. Zoga, J.A. Abboud, George Koulouris, and William B. Morrison

Glenoid dysplasia is an uncommon developmental abnormality of the scapula that is frequently overlooked. We report a case of severe glenoid dysplasia in a 55 year old man and demonstrate its radiographic, direct MR arthrographic and arthroscopic appearances.

### Introduction

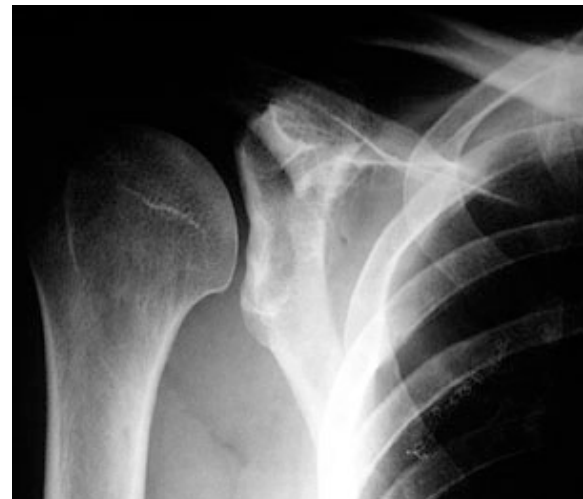Glenoid dysplasia is an uncommon but frequently overlooked developmental abnormality of the scapula that can lead to disability and morbidity in adult life. We report a case of glenoid dysplasia in a 55 year old man and demonstrate its radiographic, direct magnetic resonance (MR) arthrographic and arthroscopic appearances.

### Case Report

A 55 year old right hand dominant male builder presented with a ten week history of right shoulder pain, after a fall at work. He complained of weakness and a decreased range of motion affecting his right shoulder. The patient had not previously complained of symptoms affecting his right shoulder. The patient had a past medical history of testicular cancer, successfully treated surgically. Examination showed the following range of motion of the shoulders: Forward flexion was to 140 degrees on the right and to 160 degrees on the left, abduction to 80 degrees on the right and to 90 degrees on the left. Strength and tone examination revealed normal muscle strength. Muscle atrophy was absent and the examination was negative for liga-

mentous laxity. Laxity and stability examination revealed anterior apprehension to be negative, relocation test was negative, load and shift test was normal, the inferior sulcus sign was normal, posterior load-shift was normal as was adduction load. Impingement signs revealed positive Neer and Hawkins on the right. Nerve examination was normal as were the deep tendon reflexes.

An anteroposterior radiograph of the right shoulder showed marked hypoplasia of the scapular neck and glenoid, which had a notched appearance, compatible with the radiographic findings seen with glenoid dysplasia (Fig 1). An MR arthrogram of the right shoulder was subsequently performed and showed a markedly hypoplastic retroverted bony glenoid with a hyperplastic glenoid labrum (Fig 2). Contrast was noted to imbibe into the hy-



**Figure 1.** 55 year old male with glenoid dysplasia; radiographic findings. Anteroposterior radiograph shows marked hypoplasia of the scapular neck and glenoid, which has a notched appearance.

**Citation:** Kavanagh EC, Zoga AC, Abboud JA, Koulouris G, Morrison WB. Glenoid dysplasia: radiographic, direct MR arthrographic and arthroscopic appearances. *Radiology Case Reports*. [Online] 2006;1:20.

**Copyright:** © Eoin C. Kavanagh. This is an open-access article distributed under the terms of the Creative Commons Attribution-NonCommercial-NoDerivs 2.5 License, which permits reproduction and distribution, provided the original work is properly cited. Commercial use and derivative works are not permitted.

**Abbreviations:** MR, magnetic resonance, MRI, magnetic resonance imaging, AP, anterior posterior

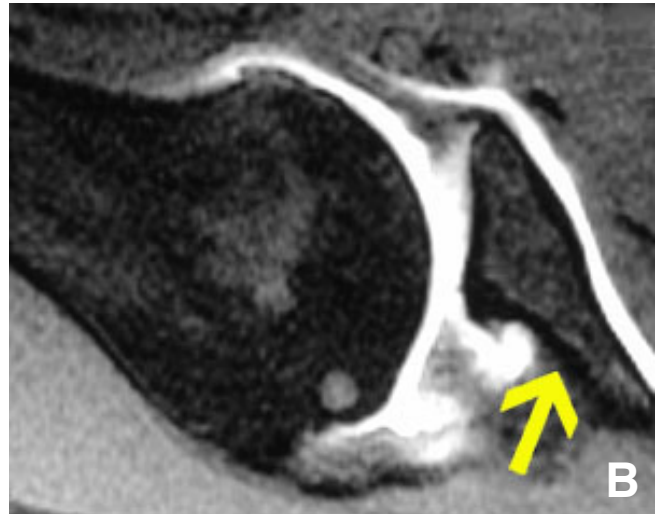
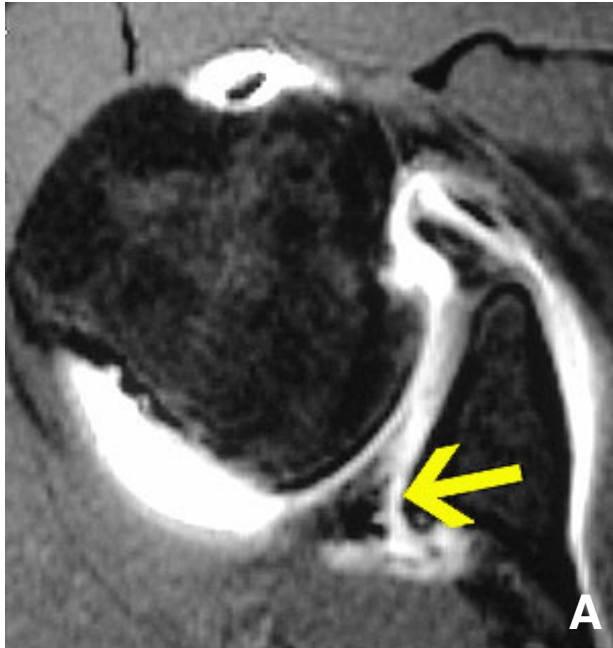
Eoin C. Kavanagh (Email: [eoinkav@yahoo.com](mailto:eoinkav@yahoo.com)), Adam Zoga, George Koulouris, and William B. Morrison are from Thomas Jefferson University Hospital, Department of Radiology, Philadelphia, PA, United States of America

J.A. Abboud is from the University of Pennsylvania School of Medicine, Department of Orthopedic Surgery, Philadelphia, PA, United States of America

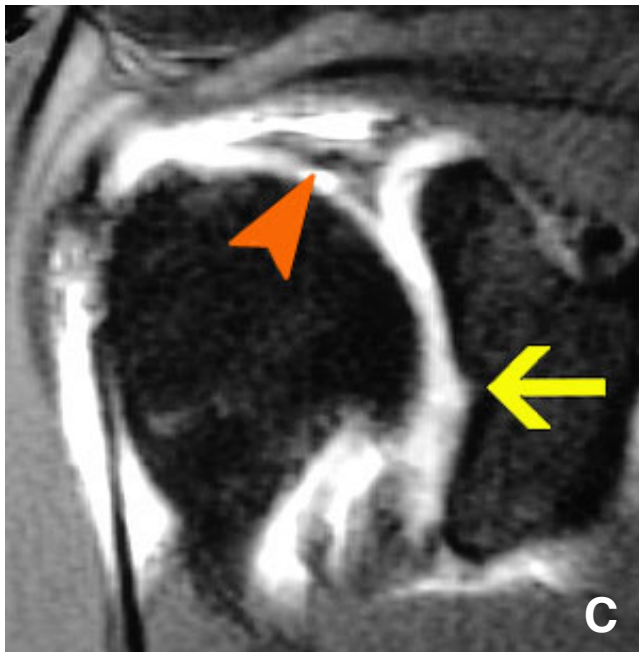
Published: June 19, 2006

DOI: 10.2484/rcr.v1i2.20

## Glenoid Dysplasia: Radiographic, Direct MR Arthrographic and Arthroscopic Appearances



**Figure 2.** 55 year old male with glenoid dysplasia; MR arthrographic findings. (A) Axial T1 weighted fat-suppressed image from direct MR arthrogram of the right shoulder shows hypoplasia and retroversion of the glenoid with marked hyperplasia of the glenoid labrum. Contrast is seen to imbibe into the hyperplastic glenoid labrum (arrow), consistent with a labral tear. (B) Axial T1 weighted fat-suppressed image from direct MR arthrogram of the right shoulder in ABER position shows hypoplasia of the glenoid and scapular neck (arrow). Note the markedly hyperplastic posterior glenoid labrum.



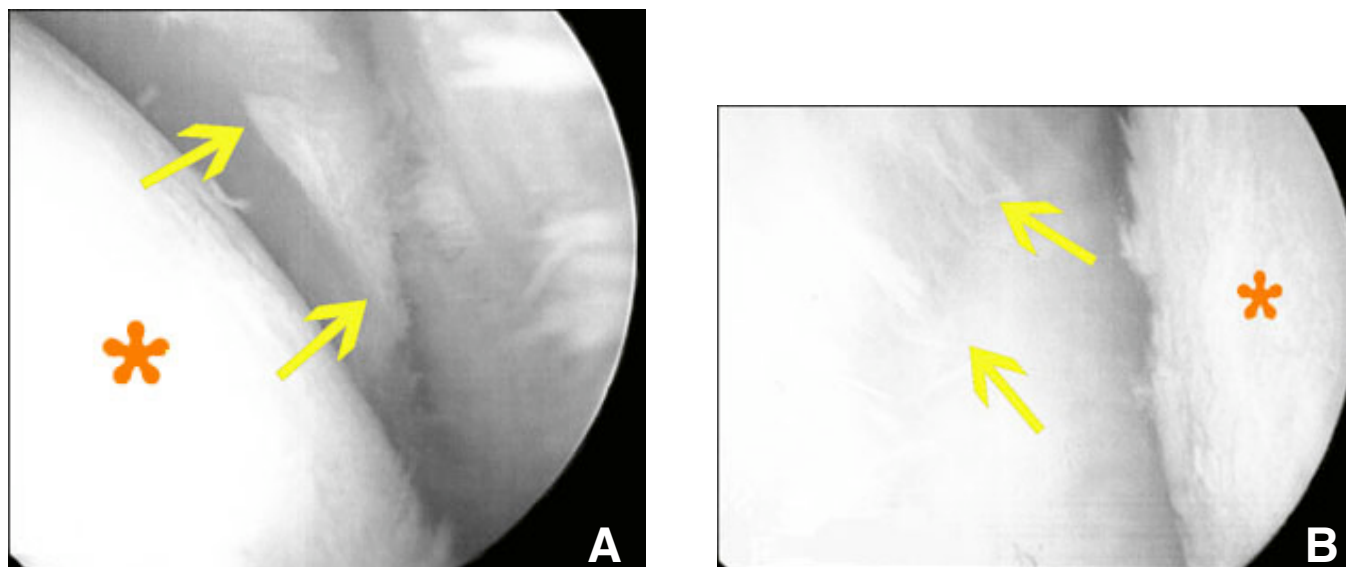
**Figure 2.** 55 year old male with glenoid dysplasia; MR arthrographic findings. (C) Coronal T1 weighted fat-suppressed image from direct MR arthrogram of the right shoulder shows characteristic notch in the glenoid (arrow), previously described on radiograph. Also note the enlarged and dysplastic superior glenoid labrum (arrowhead).

perplastic posterior labrum, consistent with a labral tear. An injection of methylprednisolone and bupivacaine was administered to the glenohumeral joint which led to symptom relief for several weeks. A course of physical therapy was also prescribed. The patient's symptoms failed to improve and an arthroscopic evaluation of the right shoulder was performed which showed a markedly hyperplastic glenoid labrum with associated labral fraying (Fig 3). There were degenerative changes typical for osteoarthritis noted at the glenohumeral joint. A partial labral debridement and an acromioplasty was performed. Postoperatively the patient has made a good recovery and is currently doing well with resolution of most of his symptoms at short term follow up.

### Discussion

Glenoid dysplasia is a rare developmental disorder that was initially described by Valentine in 1931 [1]. The true incidence of glenoid dysplasia is unknown but the fact that this lesion has been frequently reported in literature over many years, leads us to the conclusion that this may be more common than is traditionally thought. Glenoid dysplasia is seen with equal frequency in both men and women, and is frequently bilateral (up to 60% of patients). Glenoid dysplasia is usually a solitary abnormality but this disorder has been described in association with multiple epiphyseal dysplasia, deficiencies of Vitamin C and D, muscular dystrophies and many rare congenital abnormali-

### Glenoid Dysplasia: Radiographic, Direct MR Arthrographic and Arthroscopic Appearances



**Figure 3.** 55 year old male with glenoid dysplasia; arthroscopic findings. (A) Arthroscopic image shows a markedly hyperplastic glenoid labrum with irregular borders (arrows). Humeral head (\*) is to the left of the image. (B) Arthroscopic image shows the markedly irregular borders of the dysplastic glenoid labrum (arrows). Humeral head (\*) is to the right of the image.

ties [2]. The precise etiology of glenoid dysplasia is unknown but familial cases have been reported [3,4].

Most of the scapula is formed by intramembranous ossification, arising from at least eight separate centers. At birth most of the scapula is ossified. There are two separate ossification centers for the glenoid; an upper glenoid center which gives rise to the base of the coracoid and the upper third of the glenoid, and a lower glenoid center which is horseshoe-shaped, giving rise to the lower two thirds of the glenoid. Both the upper and lower centers typically fuse by the age of ten to twelve years. It is hypothesized that in glenoid dysplasia the inferior glenoid center (precartilage) fails to ossify. The reason for this failure of ossification is not yet known.

Glenoid dysplasia is often diagnosed as an incidental finding on chest radiography as many patients with this disorder are asymptomatic. It is therefore important for the radiologist to be aware of this abnormality. Other, previously reported presenting symptoms include shoulder discomfort and limited range of motion [5]. There have been descriptions of glenoid dysplasia in association with instability of the glenohumeral joint [6].

The radiographic findings seen in glenoid dysplasia have been well described in the literature. These include shortening of the scapular neck, elongation of the glenoid and alterations in the shape of the coracoid and clavicle [6]. The glenoid typically shows irregularity and notching in its inferior aspect (Fig 1). Widening of the inferior aspect of the glenohumeral joint has also been described, likely secondary to the associated hyperplasia of the glenoid labrum. CT arthrography has been described in glenoid hyperplasia, showing hyperplasia and fissuring of the inferior glenoid

labrum [6]. Reported findings on magnetic resonance imaging (MRI) in glenoid dysplasia include thickening of the articular cartilage of the glenoid fossa and enlargement of the posterior glenoid labrum [7]. In our case we have demonstrated the MRI equivalent of what is seen on anterior posterior (AP) radiography of the shoulder in glenoid dysplasia, with a characteristic notch in the bony glenoid (Fig 2c). Reports of conventional arthrographic findings in glenoid dysplasia also refer to fissuring of the abnormal inferior glenoid labrum [8]. This abnormal fissuring has also been demonstrated at MR arthrography [9], and was also seen in our case (Fig 2). In our case arthroscopic correlation showed a markedly hyperplastic glenoid labrum with irregular and “shaggy” borders, indicating that the glenoid labrum is in fact abnormally formed and dysplastic. Interestingly in our case the superior labrum also appeared abnormally enlarged and dysplastic on MRI and arthroscopy. The reason for this is not entirely clear, but our case may represent a more severe form of glenoid dysplasia than has been previously reported. Our case also demonstrated the presence of glenoid retroversion, an anomaly that has not been reported previously in association with glenoid dysplasia in an adult.

The treatment of glenoid dysplasia is controversial, with most authors advocating conservative measures [5,10]. If recognized early in association with instability then a glenoid osteotomy may be warranted to recreate the normal version of the glenoid. In elderly patients who present with this abnormality in association with glenohumeral arthritis, total shoulder replacement may be a consideration.

In conclusion we present the radiographic, MR arthrographic and arthroscopic findings in a 55 year old male

## Glenoid Dysplasia: Radiographic, Direct MR Arthrographic and Arthroscopic Appearances

with glenoid dysplasia. Both MR arthrography and arthroscopy demonstrated a dysplastic and hyperplastic glenoid labrum. Musculoskeletal radiologists should be aware of the imaging appearances of glenoid dysplasia on multiple modalities.

### References

1. Valentine B. Die kongenitale schulterluxation. *Orthop Chir.* 1931;55:229.
2. Currarino G, Sheffield E, Twickler D. Congenital glenoid dysplasia. *Pediatr Radiol.* 1998;28:30-37. [[PubMed](#)]
3. Borenstein ZC, Mink J, Oppenheim W, Rimoin DL, Lachman RS. Case report 665: Congenital glenoid dysplasia. *Skeletal Radiol.* 1991;20:134-136. [[PubMed](#)]
4. Weishaupt D, Zanetti M, Exner GU. Familial occurrence of glenoid dysplasia: report of two cases in two consecutive generations. *Arch Orthop Trauma Surg.* 2000;120:349-351. [[PubMed](#)]
5. Wirth MA, Lyons MB, Rockwood CA. Hypoplasia of the glenoid. A review of 16 patients. *J Bone Joint Surg Am.* 1993;75:1175-1184. [[PubMed](#)]
6. Trout TE, Resnick D. Glenoid hypoplasia and its relationship to instability. *Skeletal Radiol.* 1996;25:37-40. [[PubMed](#)]
7. Collins JI, Colston WC, Swayne LC. MR findings in congenital glenoid dysplasia. *J Comput Assist Tomogr.* 1995;19:819-821. [[PubMed](#)]
8. Resnick D, Walter RD, Crudale AS. Bilateral dysplasia of the scapular neck. *Am J Radiol.* 1982;139:387-389. [[PubMed](#)]
9. Munshi M, Davidson JM, Unilateral glenoid hypoplasia: unusual findings on MR arthrography. *Am J Radiol.* 2000;175:646-648. [[PubMed](#)]
10. Sperling JW, Cofield RH, Steinman SP. Shoulder arthroplasty for osteoarthritis secondary to glenoid dysplasia. *J Bone Joint Surg Am.* 2002;84:541-546. [[PubMed](#)]